

Clare Rusbridge BVMS PhD DipECVN MRCVS
European and RCVS and European Specialist In Veterinary Neurology

Stone Lion Veterinary Hospital

**41 High Street,
Wimbledon,
London, SW19 5AU
Tel: +44 (0)208 946 4228**

Date: 20/02/2010

To whom it may concern:

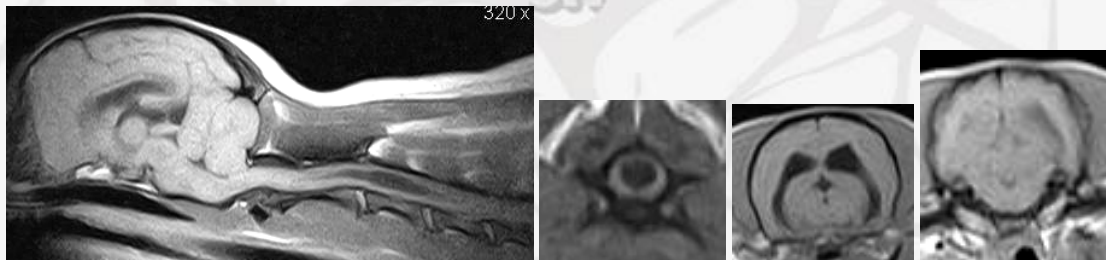
This is to confirm that on the above date the magnetic resonance images (MRI) of **Wimbledon Flora** (Flo) – **AK000000000** obtained on **22 April 2010** were reviewed

Ruby CKCS, female, DOB **22nd July 2002** , microchip 4000000000000

Owner – **A Known**

These images reveal:

- Chiari like malformation of the caudal skull **YES**
- Dilatation of the central canal / syringomyelia **YES –region C2-C4 max width 5mm**
- Ventricular dilatation **moderate**
- Mucoid material in **both** tympanic bullae



Flo presented with a several month history of signs suggesting pain. Unwilling to exercise and to jump, she had a tendency to yelp but pain could not be localised to a specific area. She often groaned when being picked up and spent a lot of time sleeping.

Using the informal CKCS classification scheme the grade of **F** would be attributed to this individual.

Clare Rusbridge BVMS PhD DipECVN MRCVS
RCVS and European Specialist In Veterinary Neurology



For information on all aspects of syringomyelia visit
<http://www.veterinary-neurologist.co.uk>