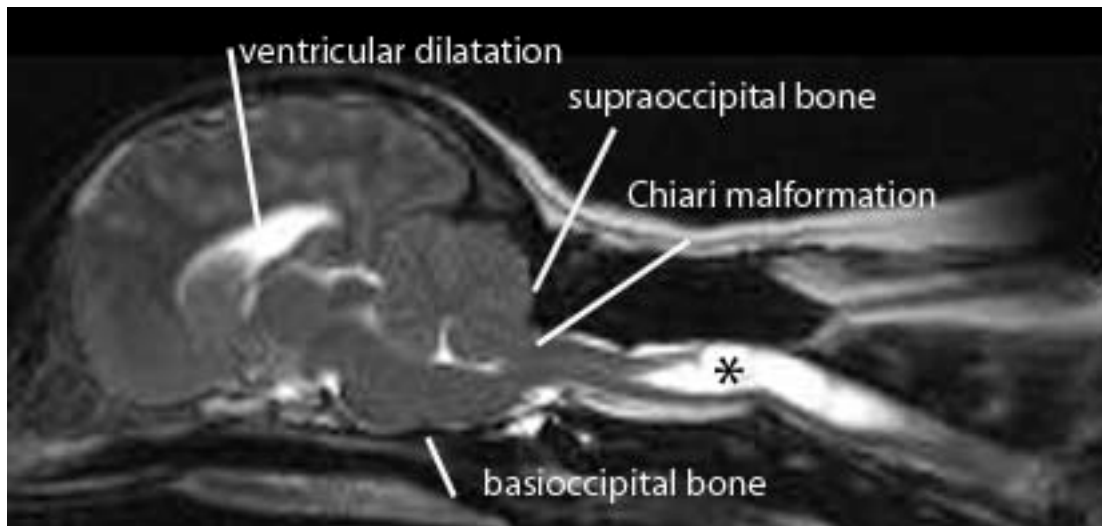


CANINE CHIARI-LIKE MALFORMATION AND SYRINGOMYELIA

Syringomyelia (SM) is characterised by fluid filled cavities within the spinal cord. SM occurs secondary to obstruction of cerebrospinal fluid (CSF) especially if that obstruction is at the foramen magnum. The most common predisposing cause in the dog is Chiari-like malformation (CM) (Rusbridge and others 2006). The primary clinical sign of CM/SM is pain, either due to obstruction of the CSF pulse pressure and/or a neuropathic pain syndrome due to damage to the spinal cord dorsal horn.

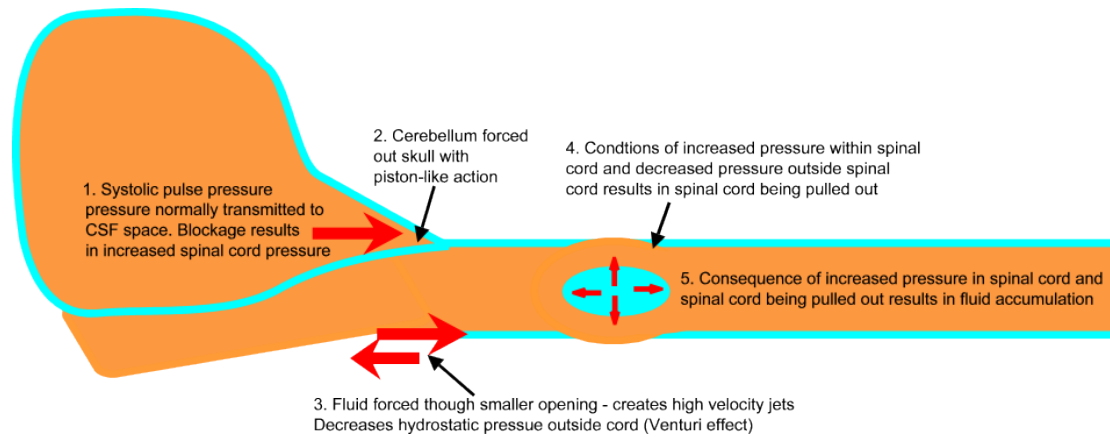


Chiari-like malformation (CM) is a condition characterised by disparity in size between the brain (too big) and the caudal fossa (too small) such that the cerebellum and brain stem are herniated into or through the foramen magnum (Cross et al 2009).

PATHOGENESIS

The pathogenesis of canine CM/SM is not fully understood. An important contributory factor is thought to be the mismatch in size between the brain and skull volume. Studies in the Griffon Bruxellois (Rusbridge et al 2009) have suggested that CM is characterised by a shortening of the basicranium and supraoccipital bone with a compensatory lengthening of the cranial vault especially the parietal bone. This has led to the hypothesis that the condition may be due to insufficiency of the bone and/or craniosynostosis of the lambdoid (occipitoparietal) and cranial base sutures.

The precise pathogenetic mechanism of development of syringomyelia is much debated (reviewed by Rusbridge et al, 2006; Greiz, 2006). A popular theory is that obstruction of CSF flow results in relative increase in spinal cord pressure and decrease in pressure in the CSF space around the spinal cord, the consequence of which is repeated mechanical distention of the spinal cord. This in turn results in dilatation of the central canal and accumulation of tissue fluid which eventually coalesces into cavities.

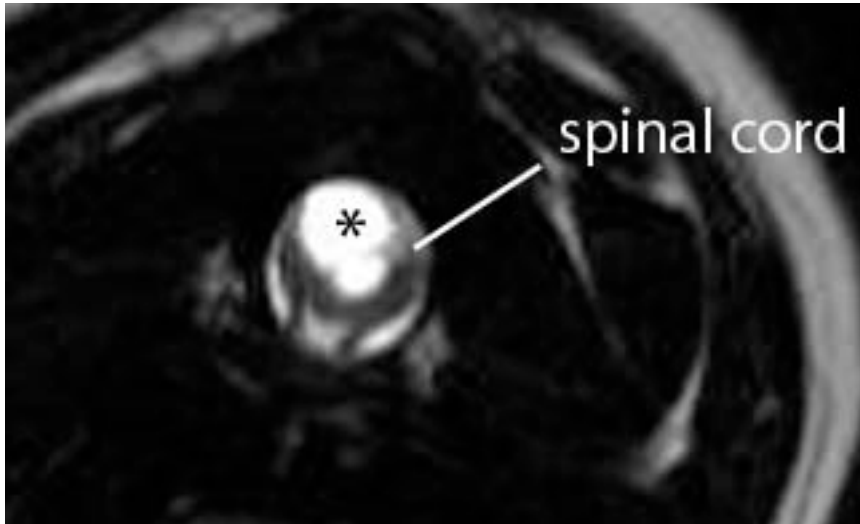


One of the enigmas of CM/SM is the difficulty of predicting / explaining which dogs with CM will subsequently develop SM. CM is almost ubiquitous in Cavalier King Charles spaniels (CKCS); Cerda-Gonzalez et al (2009) found that 92% had at least one craniocervical morphologic abnormality detected in MR images. However severity of the CM does not predict the presence of SM (Caruthers et al 2006 Cerda-Gonzalez et al, 2009) although CKCS with clinical signs related to syringomyelia are more likely to have a smaller ratio of cauda fossa (i.e. back of skull) volume to total brain volume compared to unaffected CKCS (Cerda-Gonzalez et al 2009). This suggests that there are other unidentified anatomical or environmental factors influencing the development of SM. Both CM and SM have been shown to be inherited in the CKCS (Lewis 2009; personal communication).

INCIDENCE

The CKCS is overwhelmingly overrepresented for cases of CM/SM. There is no colour or sex predisposition. As shortened skull is a risk factor, any breed with a degree of brachycephalism and/or miniaturization could potentially be predisposed to CM/SM. To date the condition has been also reported in King Charles spaniels, Griffon Bruxellois, Yorkshire terriers, Maltese terriers, Chihuahuas, Miniature dachshunds, Miniature/toy poodles, Bichon Frisé, Pugs, Shih Tzus, Pomeranians, Staffordshire bull terriers, Boston terriers, French bulldogs a Pekingese, a miniature Pinscher and a couple of cats.

Not all dogs with SM have clinical signs. The presence of signs is correlated to the width of the syrinx and extent of spinal cord dorsal horn damage. Syrinxes can progressively expand and a dog which is asymptomatic in early life may eventually become painful.



T2 weighted transverse image through a wide syrinx (asterisks) demonstrating the asymmetrical involvement of the right spinal cord dorsal horn.

The clinical course may be acute or run an extended course over several months or years. The youngest reported dogs with SM have been 12 weeks old. Dogs may be presented at any age although the majority of dogs (approximately 45%) will develop first signs of the disease within the first year of life and approximately 40% of cases have first signs between 1 and 4 years old. As many as 15% develop signs as mature dogs with the oldest reported case first developing signs of disease aged 6.8 years. Due to the vague nature of signs in some cases and lack of awareness about the disease there is often a considerable time period (mean 1.6 years) between the onset of signs and confirmation of a diagnosis.

CLINICAL SIGNS

The most important and consistent clinical sign of CM/SM is pain however this may be difficult to localise. Owners may describe postural pain; for example, affected dogs may suddenly scream and/or lie with the head on the ground between the paws after jumping up or during excitement. It is also common to sleep with the head in unusual positions, for example elevated. Discomfort often appears worse in the evening and early morning or when excited and can be associated with defaecation or may vary with weather conditions. Pain is positively correlated with syrinx width and symmetry i.e. dogs with a wider asymmetrical syrinx are more likely to experience discomfort, and dogs with a narrow syrinx may be asymptomatic, especially if the syrinx is symmetrical. Dogs with a wide syrinx may also scratch, typically on one side only, while the dog is walking and often without making skin contact, such behaviour is often referred to as an “air guitar” or “phantom” scratching. Dogs with a wide syrinx are also more likely to have scoliosis. In many cases the scoliosis slowly resolves despite persistence of the syrinx.

SM may result in other neurological deficits such as thoracic limb weakness and muscle atrophy (due to ventral horn cell damage) and pelvic limb ataxia and weakness (due to white matter damage or involvement of the lumbar spinal cord by the syrinx). Seizures, facial nerve paralysis and deafness may also be seen; however, no direct relationship has been proven and this association may be circumstantial.

CM alone appears to cause facial pain in some dogs with owners describing ear and facial rubbing/scratching. It has been proposed that CM and compression of the brain stem can result a pain syndrome (Thimineur et al, 2002). In this circumstance it can be difficult to be certain that the CM, as apposed to ear, oral or skin disease, is the cause of the distress especially as CM is a common incidental finding in the CKCS breed.

DIAGNOSIS

Magnetic resonance imaging (MRI) is essential for diagnosis and determining the cause of SM. In the instance of CM/SM the cerebellum and medulla extend into or through the foramen magnum which is occluded with little or no CSF around the neural structures. The size of the cerebellar herniation is not correlated with severity. There is typically ventricular dilatation. SM is indicated by fluid-containing cavities within the spinal cord. The upper cervical and upper thoracic segments are typically most severely affected. Maximum syrinx width is the strongest predictor of pain, scratching behaviour and scoliosis; 95% of CKCS with a maximum syrinx width of 0.64cm or more will have associated clinical signs (Rusbridge et al 2007).

CT and radiographs have limited value. CM is appreciable on radiographs and, in the Griffon Bruxellois, a ratio of the height to the length of the caudal skull can be used to predict CM (sensitivity 87%, specificity of 78%). However this is likely to be more of value in predicting the breeding value of a dog rather than as a diagnostic test for SM (Rusbridge et al 2009). In cases with severe syringomyelia cervical images may suggest widening of the vertebral canal especially in the C2 region and/or scoliosis. Radiographs are of greatest value in ruling out other vertebral abnormalities such as atlantoaxial subluxation and for an indication of the likelihood of intervertebral disc disease. Other abnormalities of the craniocervical regions which may be seen in dogs with CM/SM are occipital dysplasia i.e. wide foramen magnum (Rusbridge and Knowler 2006), atlantoaxial subluxation (Stalin and others 2008) and dens abnormalities (Bynevelt and others 2000). Myelography is not recommended for animals suspected to have CM/SM. CM/SM does not appear to increase risk of anaesthesia.

DIFFERENTIAL DIAGNOSIS

The most important differential diagnoses are other causes of pain and spinal cord dysfunction such as intervertebral disc disease; CNS inflammatory diseases such as granulomatous meningoencephalomyelitis; vertebral abnormalities such as atlantoaxial subluxation; neoplasia; and discospondylitis. When scratching or facial/ear rubbing is the predominant clinical sign, ear and skin disease should be ruled out. The scratching behaviour for SM is classically to one distinct area. It is a common incidental finding for CKCS to have a mucoid material in one or both tympanic bullae and in the majority of cases this is not associated with clinical signs. Some cases with scoliosis appear to have a head tilt which could be confused with vestibular dysfunction. If in doubt cervical radiographs can confirm scoliosis.

TREATMENT

The main treatment objective is pain relief. The most common surgical management is cranial/cervical decompression (also described as foramen magnum or suboccipital decompression) establishing a CSF pathway via the removal of part of the

supraoccipital bone and dorsal arch of C1. This may be combined with a durotomy (incision of the dura with/without incision of subarachnoid meninges) with or without patching with a suitable graft material. Cranial/cervical decompression surgery is successful in reducing pain and improving neurological deficits in approximately 80% of cases and approximately 45% of cases may still have a satisfactory quality of life 2 years postoperatively (Rusbridge 2007). However surgery may not adequately address the factors leading to SM and the syrinx appears persistent in many cases (Rusbridge 2007). The clinical improvement is probably attributable to improvement in CSF flow through the foramen magnum. In some cases scarring and fibrous tissue adhesions over the foramen magnum seem to result in re-obstruction and 25% to as many as 50% of cases can eventually deteriorate (Dewey et al 2005, Rusbridge 2007). This can be as early as 2 months postoperatively. Recently, a cranioplasty procedure used in human cranial/cervical decompression surgery has been adapted for use in dogs. The procedure entails placement of a plate constructed of titanium mesh and polymethylmethacrylate (PMMA) on pre-placed titanium screws bordering the occipital bone defect (Dewey et al 2007). An alternative method of managing SM is direct shunting of the cavity. In humans this is not a preferred technique as long term outcome is poor due to shunt obstruction and/or spinal cord tethering.

Due to the persistence of SM and/or spinal cord dorsal horn damage it is likely that the post-operative patient will also require continuing medical management for pain relief and in some patients medical management alone is chosen because of financial reasons or owner preference. There are three main drugs used for treatment of CM/SM: drugs that reduce CSF production; analgesics; and corticosteroids (Treatment Algorithm). If the dog's history suggests postural pain or discomfort relating to obstruction of CSF flow then a trial of a drug which reducing CSF pressure, e.g. furosemide, cimetidine or omeprazole, is appropriate. This can also be very useful if it is difficult to determine if the cause of discomfort is CM versus, for example, ear disease. CSF pressure reducing drugs may be sufficient to control signs in some dogs, but additional analgesics are likely to be necessary for an individual with a wide syrinx. In this circumstance we suggest that non steroidal anti-inflammatory drugs are the medication of first choice partly because there are several licensed products. However, for dogs with signs of neuropathic pain, i.e. allodynia and scratching behaviour (suspected dysesthesia); a drug which is active in the spinal cord dorsal horn is more likely to be effective. Because gabapentin has established use in veterinary medicine we suggest that this is the drug of first choice but amitriptyline or pregabalin may also be suitable. Corticosteroids are an option if pain persists or where available finances prohibit the use of other drugs. Because the mechanisms of development of neuropathic pain are multifactorial, appropriate polypharmacy is likely to be more effective than treatment with single agents. Anecdotally, acupuncture and ultrasonic treatments have been reported to be useful adjunctive therapy in some cases. The dog's activity need not to be restricted but owner should understand that dog may avoid some activities and grooming may not be tolerated. Simple actions, for example raising the food bowl and removing neck collars, can also help.

PROGNOSIS

Prognosis for CM/SM managed medically is guarded especially for dogs with a wide syrinx and/or with first clinical signs before 4 years of age. Study of a small case series (14 CKCS) managed conservatively for neuropathic pain suggested that 36%

were eventually euthanatized as a consequence of uncontrolled pain. However 43% of the group survived to be greater than 9 years of age (average life expectancy for a CKCS is 10.7 years). Most dogs retain the ability to walk although some may be significantly tetraparetic and ataxic.

BREEDING RECOMMENDATIONS.

It is recommended that breeders screen their stock for syringomyelia. Current breeding recommendations for CKCS concentrate on removal of dogs with early onset SM (i.e. within the first 2.5 years of life) from the breeding pool

REFERENCES AND FURTHER READING

- Bynevelt M, Rusbridge C, Britton J. 2000 Dorsal dens angulation and a Chiari type malformation in a Cavalier King Charles Spaniel. *Vet Radiol Ultrasound*. Nov-Dec;41(6):521-4.
- Carruthers H, Rusbridge C, Dubé, M-P, et al Association between cervical and intracranial dimensions and syringomyelia in the cavalier King Charles spaniel In: Rusbridge C, Chiari-like malformation and Syringomyelia in the Cavalier King Charles spaniel. ISBN 90-393-4456-6; 978-90-393-4456-9. 82, 2006
- Cerda-Gonzalez S, Olby NJ, Pease TP: Morphology of the Caudal Fossa in Cavalier King Charles Spaniels. *Veterinary Radiology & Ultrasound*, Vol. 50, No. 1, 2009, pp 37–46.
- Corfield GS, Burrows AK, Imani P, Bryden SL The method of application and short term results of tympanostomy tubes for the treatment of primary secretory otitis media in three Cavalier King Charles Spaniel dogs.. *Aust Vet J*. 2008 Mar;86(3):88-94
- Cross HR, Cappello R, Rusbridge C 2009 Chiari-like Malformation in Cavalier King Charles Spaniels: volumetric comparison, In Press
- Dewey CW, Bailey KS, Marino DJ, et al. 2007 Foramen magnum decompression with cranioplasty for treatment of caudal occipital malformation syndrome in dogs. *Vet Surg*. Jul;36(5):406-15.
- Dewey CW, Berg JM, Barone G et al: Foramen magnum decompression for treatment of caudal occipital malformation syndrome in dogs. *J Am Vet Med Assoc* 227: 1270, 2005
- Greitz D: Unravelling the riddle of syringomyelia. *Neurosurg Rev* 29:251, 2006
- Levine DN: The pathogenesis of syringomyelia associated with lesions at the foramen magnum: a critical review of existing theories and proposal of a new hypothesis. *J Neurol Sci*; 220:3, 2004.
- Rusbridge C, Greitz D, Iskandar BJ: Syringomyelia: Current concepts in pathogenesis, diagnosis and treatment. *J Vet Internal Med* 20: 469, 2006
- Rusbridge C, Knowler SP 2006 Coexistence of occipital dysplasia and occipital hypoplasia/syringomyelia in the cavalier King Charles spaniel.. *J Small Anim Pract*. Oct;47(10):603-6.
- Rusbridge C, Knowler SP, Pieterse L, McFadyen A. K 2009 Chiari-like Malformation in the Griffon Bruxellois *Journal of Small Animal Practice* Awaiting Publication
- Rusbridge C, Knowler SP: Inheritance of occipital bone hypoplasia (Chiari type I malformation) in cavalier King Charles spaniels. *J Vet Internal Med*; 18:673, 2004.
- Rusbridge, C 2007 Chiari-like malformation with syringomyelia in the cavalier King Charles spaniel; long term follow up after surgical management *Vet Surg* 36:396–405.
- Rusbridge, C. & Jeffery N.D. 2008 Pathophysiology and treatment of neuropathic pain associated with syringomyelia *The Veterinary Journal* 175 164–172
- Rusbridge, C., Carruthers, H., Dubé, M-P., Holmes, M., Jeffery, N.D., 2007. Association between spinal cord dorsal involvement and pain in syringomyelia secondary to canine Chiari malformation. *Journal of Small Animal Practice* 48, 432–436
- Stalin CE, Rusbridge C, Granger N, Jeffery ND. 2008 Radiographic morphology of the cranial portion of the cervical vertebral column in Cavalier King Charles Spaniels and its relationship to syringomyelia. *Am J Vet Res*. Jan;69(1):89-93
- Thimineur M, Kitaj M, Kravitz E et al: Functional abnormalities of the cervical cord and lower medulla and their effect on pain: observations in chronic pain patients with incidental mild Chiari I malformation and moderate to severe cervical cord compression. *Clin J. Pain* 18:171, 2002